



Surgical dislocation of the hip in patients with femoroacetabular impingement: Surgical techniques and our experience

Hirurška dislokacija kuka kod bolesnika sa femoroacetabularnim impingementom: hirurške tehnike i naše iskustvo

Marko Mladenović*, Zoran Andjelković†, Ivan Micić**‡, Desimir Mladenović**‡, Predrag Stojiljković*, Tanja Milenković‡

*Orthopaedics and Traumatology Clinic, Clinical Center Niš, Niš, Serbia; †Department of Orthopaedics and Traumatology, General Hospital, Leskovac, Serbia; ‡Faculty of Medicine, University of Niš, Niš, Serbia

Abstract

Background/Aim. Arthrosis of the hip is the most common cause of a hip joint disorders. The aim of this study was to present our experience in the application of a safe surgical dislocation of the hip in patients with minor morphological changes in the hip joint, which, through the mechanism of femoroacetabular impingement, cause damage to the acetabular labrum and adjacent cartilage as an early sign of the hip arthrosis. **Methods.** We have operated 51 patients with different morphological bone changes in the hip area and resultant soft tissue damage of the acetabular labrum and its adjacent cartilage. Surgical technique that we applied in this group of patients, was adapted to our needs and capabilities and it was minimally modified compared to the original procedure. **Results.** The surgical technique presented in this paper, proved to be a good method of treatment of bone and soft tissue pathomorphological changes of the hip in patients with femoroacetabular impingement. We had no cases with avascular necrosis of the femoral head, and two patients had nonunion of the greater trochanter, 9 patients developed para-articular ossification, without subjective symptoms, while 3 patients suffered from postoperative pain in the groin during more energetic physical activities. **Conclusion.** Utilization of our partly modified surgical technique of controlled and safe dislocation of the hip can solve all the bone and soft tissue problems in patients with femoroacetabular impingement to stop already developed osteoarthritis of the hip or to prevent mild form of it.

Key words: femoroacetabular impingement; hip joint; orthopedic procedures; methods; treatment outcome.

Apstrakt

Uvod/Cilj. Artroza je najčešći uzrok poremećaja zgloba kuka. Cilj rada bio je da se prikažu naša iskustva u primeni hirurške dislokacije kuka kod bolesnika sa malim morfološkim promenama u predelu kuka koje mehanizmom femoroacetabularnog impingementa, izazivaju oštećenje labruma acetabuluma i njemu susedne hrskavice koji su znaci rane artroze kuka. **Metode.** Operisali smo 51 bolesnika sa različitim morfološkim koštanim promenama u predelu kuka i posledičnim mekotičnim oštećenjima labruma acetabuluma i njemu susedne hrskavice. Hiruršku tehniku koju smo primenili kod operisanih bolesnika, prilagodili smo našim potrebama i mogućnostima i minimalno modifikovali u odnosu na originalnu proceduru. **Rezultati.** Hirurška tehnika, prikazana u ovom radu, pokazala se kao dobra metoda lečenja patomorfoloških koštanih i mekotičnih promena kuka kod bolesnika sa femoroacetabularnim impingementom. Nismo imali bolesnike sa avaskularnom nekrozom femoralne glave, a kod dva bolesnika bilo je prisutno produženo srastanje osteotomije velikog trohantera. Kod 9 bolesnika razvila se paraartikularna osifikacija, bez subjektivnih tegoba, dok je kod tri bolesnika trajao postoperativni bol u preponi pri jačem naporu. **Zaključak.** Primena naše delimično modifikovane tehnike hirurške dislokacije kuka može rešiti sve probleme kostiju i mekih tkiva kod bolesnika sa femoroacetabularnim impingementom, sa ciljem da se zaustavi već razvijen osteoartritis kuka ili da se spreče njegove blage forme.

Ključne reči: femoroacetabularni sudar; kuk, zglob; ortopedске procedure; metodi; lečenje, ishod.

Introduction

Femoroacetabular impingement (FAI) is the pathophysiological mechanism of the hip, which is a consequence

of minor morphological changes in the acetabulum and/or proximal femur which reduce the physiological distance between them and cause repeated impacts of the femoral head-neck junction on the anterior and superior acetabulum edge

during hip movements. Secondary pathological changes occur due to daily repeated microtrauma of the labrum (tear, cystic degenerative changes and ossification), labrum adjacent articular cartilage and subchondral bone¹⁻¹¹. Extensive labrum damages cause groin pain and limit the function of the hip. Two basic forms of FAI were identified, based on the localization of bone changes: cam and pincer type of FAI, while, mixed type of FAI is, actually, a combination of the previous two. Cam type of FAI, with aspherical femoral head configuration, is the result of localized thickening or cam at the femoral head-neck junction, often described in the literature as a “pistol grip”^{5,12} or “tilt” deformity of the femoral head¹³, recognised in slip of the femoral head epiphysis¹⁴⁻¹⁶, Legg-Calve-Perthes disease¹⁷, femoral head avascular necrosis¹⁸ and poorly healed fractures of the femoral neck¹⁹. Pincer type of FAI is seen in the overcoverage of the femoral head by the acetabulum, as a global overcoverage (protrusio acetabuli, coxa profunda)^{2,4}, the local overcoverage in retroversio acetabuli²⁰ and in redirection osteotomies of the pelvis or in the trauma of the acetabuli^{20,21}. The impact of the femoral neck on the edge of the acetabulum, during movements, generates a system of levers arm, and produces counter impact of the femoral head on the posterior wall of the acetabuli, causing acetabular cartilage damage, known as “counter cup” lesions^{4,20}. Mixed type of FAI, the most common one in clinical practice, is a combination of the previous two, with morphological changes on the acetabulum and the femoral head-neck junction at the same time.

Specified pathoanatomical changes of the femur and acetabulum are treated only surgically, with the aim of the prevention of an early development of the hip osteoarthritis. There are two basic surgical approaches in FAI treatment, widely accepted in recent time hip arthroscopy, is applied to small-scale bone and soft tissue changes in the hip and, the other one, is open method, applied to extensive changes in the hip. The open method of surgery, described by Ganz et al.²² and Lavigne et al.²³, implies surgical dislocation of the hip.

The aim of this paper was to present and popularize the basics of the surgical techniques in patients with FAI in our material as well as the early results of surgical treatment.

Methods

From November 1999 until January 2011, we performed 54 open surgical dislocation of the hip in 51 patients with FAI. There were 36 women and 15 men with an average age of 36.1 ± 9.1 years (range 19 – 54 years) at the time of surgery. In three patients, surgery was performed bilaterally, with a period between the operations of 12 to 28 months.

The indications for the surgery were: several months of groin pain, positive impingement test and the presence of clear radiographic signs of bone hip changes.

There were 11 patients (8 men and 3 women) with cam type of FAI, 29 patients (3 men and 26 women) with pincer type of FAI, and 14 patients (4 men and 10 women) with mixed form of FAI. The average operative time was 50 min (45 to 80 min) with a blood loss of 250 mL (150 to 400 mL). The preservation of the femoral head blood flow was the basic postulate of open

surgical procedures, to prevent femoral head avascular necrosis. Medial circumflex femoral artery (ACFM) nourishes much of the femoral head in full, as a terminal branch profunda femoris artery^{24,25}. ACFM follows the lower edge of the obturator externus muscle and going below the hip external rotators and joint capsule over the posterior and superior femoral neck, it branches in 4 to 6 retinacular arteries that have been posted subperiostally and 4 to 5 mm from the epiphyseal line, enters the femoral head through the nutritional holes.

Surgical technique

The patient is situated on the healthy side with leg holder between the legs, in our environment made of sponge, dimensions $50 \times 100 \times 15$ cm, which elevates the operated leg from the operational table, relaxing the gluteal muscles and make easier access and soft tissue preparation on the hip. Skin and fascia lata incision is lateral. Posterior edge of the gluteus medius muscle, vastus lateralis muscle are identified. In the line of the greater trochanter attachment of these muscles, the line of osteotomy on the greater trochanter is marked by electrocautery, which was set to about 5 mm behind the posterior edge, thereby avoiding the trochanteric osteotomy compromise ACFM. The thickness of the osteotomized part of the greater trochanter is up to 1.5 cm, so that the attachments of the gluteus medius and *vastus lateralis* muscle remain on it. A greater trochanter is osteotomized with a saw and then lifted anteriorly. Careful preparation of the muscle fibers along the posterior edge of the *musculus gluteus medius* is done, tendon of the *musculus piriformis* and its attachment to the trochanteric fossa is visualised and retracts posteriorly. Below this tendon the body of *gluteus minimus* muscle is visualised and then carefully lift by sharp dissection from the superior and anterior part of the joint capsule (Figure 1).

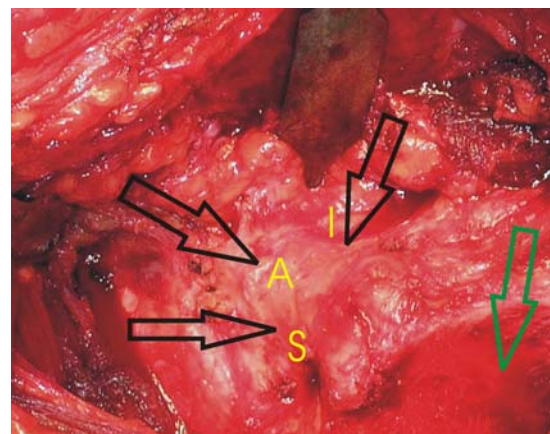


Fig. 1 – Completed dissection of the upper (S), anterior (A) and lower (I) part of the hip joint capsule (black arrow); position of the trochanteric osteotomy (green arrow).

Thus, the joint capsule is dissected, from the edge of the piriformis tendon muscle forward and downward to the lesser trochanter. After the joint capsule dissection had been completed, joint arthrotomy is made, in the form of its near acetabular attachment, in order to prevent unnecessary damage

of the acetabular labrum in the line of capsules incision. A horizontal arm of the “Z” capsule incision, extends along the base of the neck of the femur following capsule attachment to the base of a greater trochanter, to the upper edge of the lesser trochanter. Another horizontal arm of the “Z” incision of the hip joint capsules follows its attachment to the upper edge of the acetabulum, and extends posteriorly to the edge of the *musculus piriformis* tendon, and if necessary, the approach to the hip joint, can be extended lifting the tendon of *musculus piriformis* (Figure 2). Homann retractors are set on the anterior edge of the acetabulum above the acetabular *labrum* and the other one in the supraacetabular region, then moving the thigh in flexion,

lifting them from the base and from the subchondral acetabular bone, which is known as a “degloving phenomenon”. Surgical correction of primary and secondary pathological changes of the hip is determined by preoperative radiographic findings and intraoperative changes of the hip. After 2005 in all cases, where the labrum damage was not too extensive, we did reinsertion of the labrum using 2–4 bone anchors, with the prior osteotomy and refreshment of the anterior and superior edge of the acetabulum. Cam osteochondral changes on the anterior and/or superior part of the femoral head and neck junction were osteotomized, following the line of the undamaged articular cartilage of femoral head,

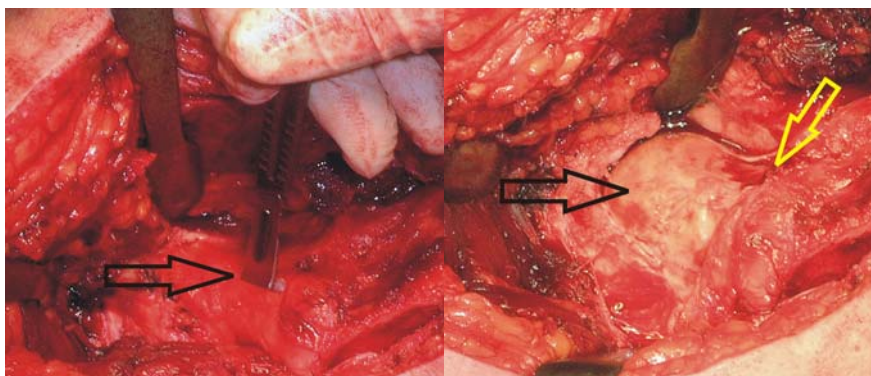


Fig. 2 – Left: Vertical arm of “Z” capsulotomy (black arrow). Right: Horizontal acetabular arm (black arrow) and horizontal trochanteric arm of “Z” capsulotomy (yellow arrow); the femoral head and neck are shown.

adduction and internal rotation under the visual control, the area of conflict-impact of the femoral head and neck with the edge of the acetabulum is identified.

After this trial of the FAI mechanism, the controlled anterior dislocation of the hip is approached, flexing, externally rotating and adducting the femur, then, crossing the thigh of the operated leg over the healthy one and putting the lower leg of the operated side in a sterile bag made from compresses. After the hip dislocation completion, it is possible to completely visualise 360° circumference of the acetabulum and femoral head, manipulating with the leg in additional adduction or abduction of the thigh (Figure 3).

strictly taking care not to compromise the zone of the retinacular blood vessels entry in the femoral head (Figure 4). After completion of the planned surgical treatment, we performed orthopedic repositioning of the femoral head, reconstructed joint capsule and screwed a part of the osteotomized greater trochanter with two cortical screws.

Results

In all of the operated patients *labrum* lesions were located in the anterior or anterosuperior region of the acetabulum. In 11 hips anterior and/or superior acetabular edge were

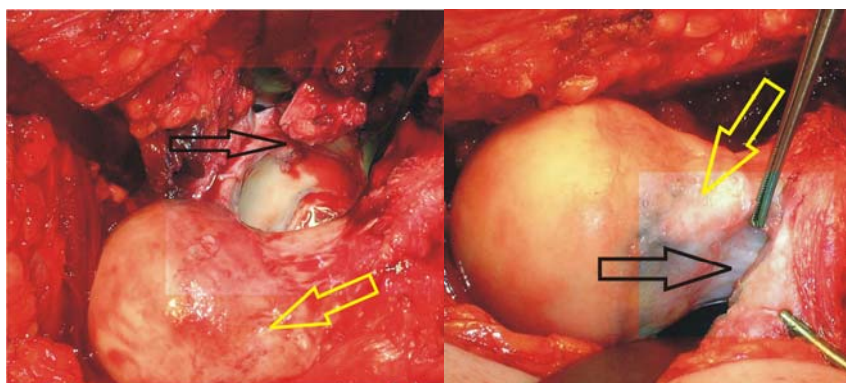


Fig. 3 – Left: Access to the 360° circumference of the hip, severe acetabular *labrum* lesion (black arrow), cam-deformity at the junction of the femoral head and neck (white arrow). Right: Cam deformity of the femoral neck (yellow arrow), the position of retinacular blood vessels in relation to cam-deformity (black arrow).

Using the dental hook, *labrum* lesion and the part of the articular cartilage, adjacent to the *labrum* lesion is identified,

osteotomized and *labrum* was refixed to the bone with 2–4 anchor sutures and in 43 hips the damaged part of the *lab-*

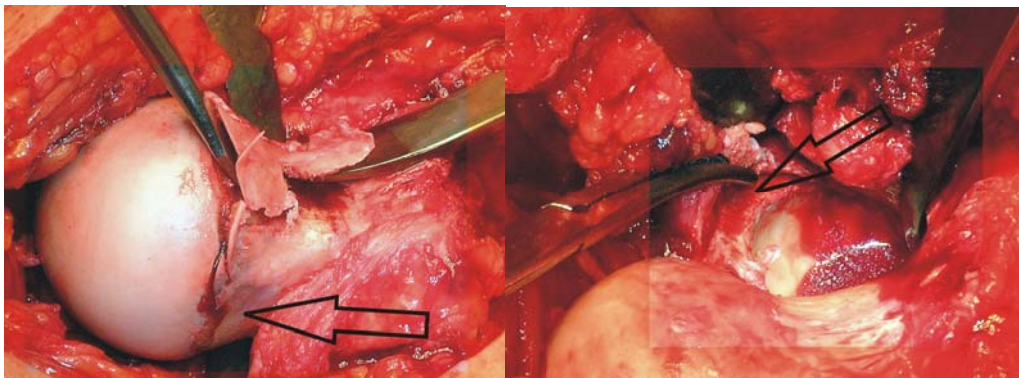


Fig. 4 – Left: Osteochondroplasty of cam-deformity at the femoral head-neck junction, position of the retinacular blood vessels of the femoral head (black arrow). Right: partially resected badly damaged acetabular *labrum* and osteotomy of the anterior edge of the acetabulum (black arrow).

rum was resected with planned osteotomy of the edge of the retroverted acetabulum.

In 20 patients with cam and mixed type of FAI, lifted acetabular cartilages from subchondral bone were found, so-called “degloving phenomena”, in the *labrum* lesion area (15–20 mm width, and 5–15 mm depth towards the fossa acetabuli) without any appropriate therapeutic possibility to solve this problem. In pincer type FAI patients, chondral lesions occurred in two places: one, in the impact area, as the acetabulum *labrum* lesions, and the damaged zone of cartilage roughness, softening and hyperemia, and the other one, the counter-cup acetabular cartilage lesions, in the postero-inferior acetabular region, with, also, softening, hyperemia and fissurization of the acetabular articular cartilage.

Femoral head-neck junction osteochondral cam deformity, were found in anterior and mostly, superior part, in all patients with cam type of FAI and, only, in the anterior part of the femoral head-neck junction in the patients with mixed type of FAI. Macroscopically, cam deformity was clearly demarcated by a semicircular line, protruded above the femoral head circumference and compromised sphericity of the femoral head and neck circumference, covered with rough, hyperaemic cartilage tissue. Cam deformity was osteotomized up to the level of the femoral neck taking care not to osteotomise more than 30% of the thickness of the neck²⁶. In patients with pincer type of FAI, it was very difficult to determine, how much of the acetabular edge osteotomy was enough to prevent postoperative re-impact of the femoral neck on the edge of the acetabulum on one side, and how to avoid anterior insufficient coverage of the femoral head due to excessive resection of the acetabular edge on the other side. Osteotomy of the femoral head-neck junction was done in all the patients with pincer type of FAI.

Our clinical results (Table 1) confirm the validity of the method applied in the treatment of symptomatic hips with different types of FAI. All the patients showed improvement in internal rotation of the thigh in the hip joint, hip flexion was not significantly changed, and the groin pain ceased, except for three women operated with pincer type FAI with protrusion of the acetabulum, where a mildly positive impingement tests were found, and the reason for this as assumed, was the lack of radical resection of the anterior edge of the acetabulum.

Postoperative complications: neuropraxia of the main nerves of the leg (*nervus ischiadicus*, *nervus femoralis*), postoperative deep vein thrombosis of the operated leg, patients with avascular necrosis of the femoral head as the result of violation of its vascularization were not found. In 9 of the patients asymptomatic postoperative paraarticular osifications were developed as incidental radiographic findings at radiographic control examinations. Trochanteric osteotomies were healed on the average of 6–8 weeks, but in two patients, due to premature full weight bearing on the operated leg, slow healing of osteotomy of the greater trochanter was observed. In one patient it was enough to restrict weight bearing on the operated leg for up to 2 months, osteotomy to heal, and in one patient, 9 months after the prime operation, refixation of the great trochanter of the femur was done, which healed 3 months after the second operation.

Table 1
Early clinical preoperative and postoperative results in operated patients with different forms of femoroacetabular impingement

Parameter	Preoperative	Postoperative
Positive impingement test (n)	54	0
Groin pain (n)	54	3
Hip internal rotation (°)	0–15	20–35
Hip flexion (°)	70–90	80–90

n – number of patients.

Discussion

The interest in the problem of femoroacetabular impingement in the world is increasingly progressing as measured by the number of published papers on this subject. So, 10 papers were published in 2004, 44 papers in 2007 and, in recent years, the number of publications, per year, has exceeded 100²⁷. In our country, unfortunately, only one paper on this subject was published²⁸, and the number of treated patients, compared to the literature data, is significantly lower than the world's epidemiological data. This paper presents our initiative in approaching the femoroacetabular impingement and our desire to pay much more attention to this matter, in the future.

Athroscopic FAI surgery is the most commonly used method in the treatment of mild types of FAI, which is often combined with the minimally invasive open method of femoral head and neck cam deformity resection²⁹, which could not be performed due to technical reasons at our institution.

This is confirmed by our early results presented in a series of patients, due to the fact that patients did not have complications such as avascular necrosis of the femoral head.

Surgical debridement of the hip is indicated in young adults with or without initial arthrotic changes to the hip, for which, the problem of hip pain can be solved and the development of arthrosis stopped or prevented. Osteochondroplastic of femoral neck bears the risk of femoral neck fracture if more than 30% of its thickness is being osteotomized^{26,30}. In all the present-

ed patients, femoral head and neck osteochondroplastic were done without iatrogenic postoperative femoral neck fracture.

Conclusion

Based on the previously described facts and material and our partly modified surgical technique of controlled and safe dislocation of the hip in treatment of patients with all types of femoroacetabular impingement, we believe this method to be an excellent therapeutic method. Utilization of this method can solve all bone and soft tissue problems in patients with femoroacetabular impingement aimed to stop already developed osteoarthritis of the hip, or to prevent mild forms of it.

REFERENCES

1. Beck M, Kalhor M, Leunig M, Ganz R. Hip morphology influences the pattern of damage to the acetabular cartilage: femoroacetabular impingement as a cause of early osteoarthritis of the hip. *J Bone Joint Surg Br* 2005; 87(7): 1012–8.
2. Beck M, Leunig M, Parvizij J, Boutier V, Wyss D, Ganz R. Anterior femoroacetabular impingement: part II. Midterm results of surgical treatment. *Clin Orthop Relat Res* 2004; 418: 67–73.
3. Burnett RS, della Rocca GJ, Prather H, Curry M, Maloney WJ, Clobisoy JC. Clinical presentation of patients with tears of the acetabular labrum. *J Bone Joint Surg Am* 2006; 88: 1448–57.
4. Ganz R, Parvizij J, Beck M, Leunig M, Nötzli H, Siebenrock KA. Femoroacetabular impingement: a cause for osteoarthritis of the hip. *Clin Orthop Relat Res* 2003; 417: 112–20.
5. Harris WH. Etiology of osteoarthritis of the hip. *Clin Orthop Relat Res* 1986; 213: 20–33.
6. Ito K, Minka MA, Leunig M, Werlen S, Ganz R. Femoroacetabular impingement and the cam-effect: a MRI-based quantitative anatomical study of the femoral head-neck offset. *J Bone Joint Surg Br* 2001; 83(2): 171–6.
7. Klaue K, Durnin CW, Ganz R. The acetabular rim syndrome. A clinical presentation of dysplasia of the hip. *J Bone Joint Surg Br* 1991; 73(3): 423–9.
8. Leunig M, Beck M, Woo A, Dora C, Kerboull M, Ganz R. Acetabular rim degeneration: a constant finding in the aged hip. *Clin Orthop Relat Res* 2003; 413: 201–7.
9. Leunig M, Werlen S, Ungersböck A, Ito K, Ganz R. Evaluation of the acetabular labrum by MR arthrography. *J Bone Joint Surg Br* 1997; 79(2): 230–4.
10. Peelle MW, Della Rocca GJ, Maloney WJ, Curry MC, Clobisoy JC. Acetabular and femoral radiographic abnormalities associated with labral tears. *Clin Orthop Relat Res* 2005; 441: 327–33.
11. Wenger DE, Kendall KR, Miner MR, Trousdale RT. Acetabular labral tears rarely occur in the absence of bony abnormalities. *Clin Orthop Relat Res* 2004; 426: 145–50.
12. Stulberg SD, Cordell LD, Harris WH, Ramsey PL, Macewen GD. Unrecognized childhood hip disease: a major cause of idiopathic osteoarthritis of the hip. In: *Amstutz HC*, editor. *The Hip: Proceedings of the Third Open Scientific Meeting of the Hip Society*. St Louis, MO: CV Mosby; 1975. p. 212–28.
13. Murray RO. The aetiology of primary osteoarthritis of the hip. *Br J Radiol* 1965; 38(455): 810–24.
14. Siebenrock KA, Wabab KH, Werlen S, Kalhor M, Leunig M, Ganz R. Abnormal extension of the femoral head epiphysis as a cause of cam impingement. *Clin Orthop Relat Res* 2004; 418: 54–60.
15. Goodman DA, Feighan JE, Smith AD, Latimer B, Buly RL, Cooperman DR. Subclinical slipped capital femoral epiphysis. Relationship to osteoarthritis of the hip. *J Bone Joint Surg Am* 1997; 79(10): 1489–97.
16. Leunig M, Casillas MM, Hamlet M, Hersche O, Nötzli H, Slongo T, et al. Slipped capital femoral epiphysis: early mechanical damage to the acetabular cartilage by a prominent femoral metaphysis. *Acta Orthop Scand* 2000; 71(4): 370–5.
17. Snow SW, Keret D, Scarangella S, Bowen JR. Anterior impingement of the femoral head: a late phenomenon of Legg-Calvé-Perthes' disease. *J Pediatr Orthop* 1993; 13(3): 286–9.
18. Kloen P, Leunig M, Ganz R. Early lesions of the labrum and acetabular cartilage in osteonecrosis of the femoral head. *J Bone Joint Surg Br* 2002; 84(1): 66–9.
19. Ejler H, Myers SR, Ganz R. Anterior femoroacetabular impingement after femoral neck fractures. *J Orthop Trauma* 2001; 15(7): 475–81.
20. Siebenrock KA, Schoeniger R, Ganz R. Anterior femoroacetabular impingement due to acetabular retroversion. Treatment with periacetabular osteotomy. *J Bone Joint Surg Am* 2003; 85-A(2): 278–86.
21. Myers SR, Ejler H, Ganz R. Anterior femoroacetabular impingement after periacetabular osteotomy. *Clin Orthop Relat Res* 1999; 363: 93–9.
22. Ganz R, Gill TJ, Gautier E, Ganz K, Krügel N, Berlemann U. Surgical dislocation of the adult hip a technique with full access to the femoral head and acetabulum without the risk of avascular necrosis. *J Bone Joint Surg Br* 2001; 83(8): 1119–24.
23. Lavigne M, Parvizij J, Beck M, Siebenrock KA, Ganz R, Leunig M. Anterior femoroacetabular impingement: part I. Techniques of joint preserving surgery. *Clin Orthop Relat Res* 2004; 418: 61–6.
24. Gautier E, Ganz K, Krügel N, Gill T, Ganz R. Anatomy of the medial femoral circumflex artery and its surgical implications. *J Bone Joint Surg Br* 2000; 82(5): 679–83.
25. Lavigne M, Kalhor M, Beck M, Ganz R, Leunig M. Distribution of vascular foramina around the femoral head and neck junction: relevance for conservative intracapsular procedures of the hip. *Orthop Clin North Am* 2005; 36(2): 171–6.
26. Mardones R, Gonzales K, Chen Q, Zobitz M, Kaufman K, Trousdale R. Femoroacetabular Impingement: Evaluation of the Effect of the Size of the Resection. *J Bone Joint Surg Am* 2005; 87(2): 273–9.

27. *Leunig M, Beaulé P, Ganz R.* The concept of Femoroacetabular Impingement. Current Status and Future Perspectives. *Clin Orthop Relat Res* 2008; 467(3): 616–22.
28. *Vukašinić Z, Spasovski D, Živković Z.* Femoroacetabular impingement related to Legg-Calvé-Perthes disease. *Srp Arh Celok Lek* 2011; 139(11–12): 834–7. (Serbian)
29. *Clobisoy JC, Zehala LP, Nepple JJ, Pashos G.* Combined hip arthroscopy and limited open osteochondroplasty for anterior femoroacetabular impingement. *J Bone Joint Surg Am* 2010; 92(8): 1697–706.
30. *Espinosa N, Beck M, Rothenfluh DA, Ganz R, Leunig M.* Treatment of femoro-acetabular impingement: preliminary results of labral refixation. Surgical technique. *J Bone Joint Surg Am* 2007; 89(Suppl 2 Pt 1): 36–53.

Received on December 7, 2013.

Accepted on October 15, 2014.

Online First September, 2015.